

# Coronoid Process Fracture

Scott P. Steinmann, MD

## Abstract

The coronoid process is one of the main constraints providing ulnohumeral joint stability. The coronoid process and the radial head provide a buttress against posterior displacement of the elbow joint. Fracture of the coronoid process can be either an isolated finding following elbow dislocation or part of a more complex fracture-dislocation. Much attention has been focused on treatment of radial head fractures and lateral ligament reconstruction, although recently, attention has been directed at detection and treatment of coronoid fractures. Surgical approaches to coronoid fractures depend on the condition of the radial head. When an associated radial head fracture is present, a lateral approach to the coronoid fracture is often performed. An isolated coronal fracture is typically approached from the medial side. Intraoperative stress testing may be helpful in assessing the need for surgery and choosing the surgical approach.

**S**urgical management of fractures of the coronoid process with open reduction and internal fixation has increased in popularity during the past few years. Previously, treatment recommendations included excision or expectant management; however, the results were often unsatisfactory. New treatment options for coronoid fractures have been developed as the effect of coronoid fracture on elbow stability has been recognized.<sup>1,2</sup>

The coronoid process is one of the primary constraints providing ulnohumeral joint stability. The coronoid and the radial head provide a buttress against posterior displacement and subluxation of the elbow joint. The radial head helps prevent valgus instability, and the coronoid helps prevent varus instability. The coronoid process extends medially from the ulna, lengthening the articular surface of the elbow and cupping the medial trochlea. When a strong varus force is applied to the

elbow, the coronoid process may fracture. Varus instability may result from the fracture and, if left untreated, will result in ulnohumeral arthritis. Surgical exposure of the coronoid process from the medial aspect of the elbow may be difficult because it is deep to the flexor pronator group.

## Anatomy

The coronoid process and the olecranon together form the greater sigmoid notch of the ulna. The coronoid process articulates with the trochlea of the humerus, and the radial head articulates with the capitellum. The radial head also articulates with the lateral portion of the coronoid and the lesser sigmoid notch. The proximal ulna is narrower than the distal humerus but widens to form the coronoid process (Figure 1). The coronoid process therefore reaches medially to match the distal articular surface of the

Dr. Steinmann is Professor of Orthopaedic Surgery, Department of Orthopaedic Surgery, Mayo Clinic, Rochester, MN.

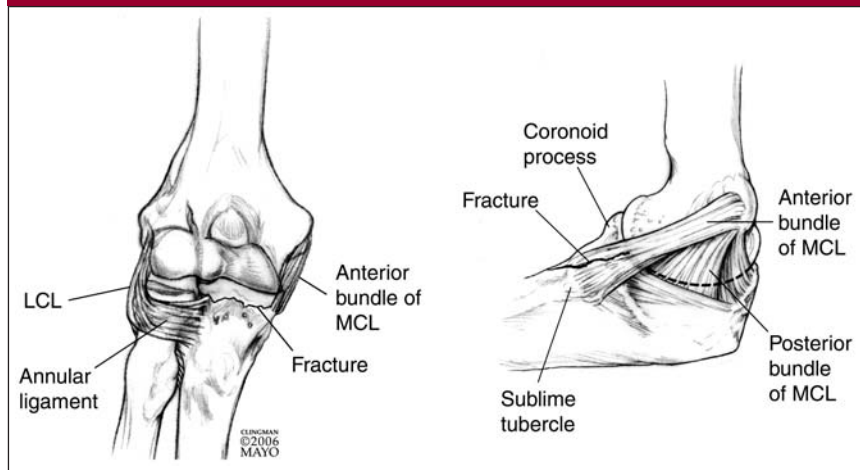
Neither Dr. Steinmann nor a member of his immediate family has received anything of value from or owns stock in a commercial company or institution related directly or indirectly to the subject of this article.

Reprint request: Dr. Steinmann, Mayo Clinic, 200 First Street SW, Rochester, MN 55905.

*J Am Acad Orthop Surg* 2008;16:519-529

Copyright 2008 by the American Academy of Orthopaedic Surgeons.

**Figure 1**



Anterior (A) and medial (B) views of the elbow demonstrating the pertinent anatomy related to coronoid process fracture. LCL = lateral collateral ligament, MCL = medial collateral ligament. (Reproduced with permission from the Mayo Foundation.)

**Table 1**

**O’Driscoll Classification of Coronoid Process Fractures**

Type	Fracture Location	Subtype	Description
I	Tip	1	≤2 mm of coronoid bony height (ie, flake fracture)
		2	>2 mm of coronoid height
II	Anteromedial	1	Anteromedial rim
		2	Anteromedial rim + tip
		3	Anteromedial rim + sublime tubercle (± tip)
III	Basal	1	Coronoid body and base
		2	Transolecranon basal coronoid fractures

Reproduced from O’Driscoll SW, Jupiter JB, Cohen MS, Ring D, McKee MD: Difficult elbow fractures: Pearls and pitfalls. *Instr Course Lect* 2003;52:113-134.

out a fracture of the radial head. Thus, in a patient with a suspected elbow dislocation, a close examination of the radiographs for a coronoid fracture is warranted. With an anteromedial coronoid fracture, the anteroposterior radiograph of the elbow will demonstrate progressive narrowing of the joint space from lateral to medial between the medial trochlea and the coronoid process. Normally, the joint space between the medial trochlea and the coronoid process is equal from lateral to medial.

On a lateral radiograph, a coronoid fracture fragment may appear small and may be confused with a radial head fracture. A computed tomography (CT) scan of the elbow is recommended in all cases of suspected coronoid fractures because such a fracture is readily seen with this imaging modality.

**Classification**

Regan and Morrey<sup>4</sup> in 1989 classified coronoid process fractures into three types, based on the lateral radiographic view: type I, avulsion of the tip of the process; type II, fragment involving ≤50% of the process; and type III, fragment involving >50% of the process. This classification predated the use of CT. With the greater use of CT scanning, it is now understood that coronoid fractures do not commonly occur as a transverse fracture of the coronoid process in the coronal plane. At the time of the study by Regan and Morrey, coronoid fractures were rarely addressed surgically; only 3 of 35 patients in the study underwent fixation of the coronoid fracture.<sup>4</sup> Nevertheless, because of its simplicity, the Regan and Morrey classification system remains the one used by most orthopaedic surgeons.

O’Driscoll et al<sup>5</sup> proposed a seven-part coronoid fracture classification system based on the anatomic location of the fracture (Table 1). This classification comprises three main types: type I, transverse fracture of

trochlea. This medial extension of the coronoid forms the sublime tubercle. On average, 60% of the anteromedial facet of the coronoid process is unsupported by the proximal ulnar metaphysis, making it prone to fracture with varus stress.<sup>3</sup> The sublime tubercle serves as the insertion site of the anterior band of the medial collateral ligament (MCL), which originates from the inferior aspect of the medial epicondyle. The

MCL provides significant resistance to valgus stress of the elbow.

**Imaging**

Coronoid process fracture may be difficult to discern on plain radiographs. The initial radiographs taken following trauma may demonstrate a small fracture fragment that is often confused for a portion of the radial head. A coronoid fracture may occur with-

the tip of the coronoid process (Figure 2); type II, fracture of the anteromedial facet of the process (Figure 3); and type III, fracture of the process at its base. This is the first classification system that takes into account realistic patterns of coronoid fracture. In particular, the type II fracture pattern (anteromedial) is one commonly seen with varus posteromedial dislocation of the elbow. Although the reliability of this classification system needs to be tested, the focus on the tip, the anteromedial facet, and the base may enhance our understanding of coronoid process fracture patterns.<sup>1</sup>

### Mechanism of Injury

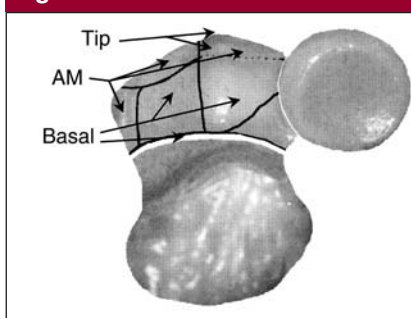
#### Coronoid Tip and the Terrible Triad

A coronoid tip fracture is often seen in conjunction with an elbow dislocation and a radial head fracture—an injury pattern commonly referred to as the “terrible triad.”<sup>1</sup> The mechanism of injury in such cases is a valgus and supination moment to the forearm. This force, if severe, will force the radial head up against and then under the capitellum, usually resulting in fracture of the radial head. As the radial head continues under the capitellum, the progressive valgus force drives the coronoid under the trochlea and shears off the tip of the coronoid process. Posterolateral rotatory displacement of the elbow occurs, and as the elbow dislocates, the lateral collateral ligament (LCL) is torn from its humeral origin. The MCL is usually preserved because the sublime tubercle is generally not fractured. The result is a transverse fracture of the anterior 2 to 3 mm of the coronoid process.

#### Anteromedial Coronoid Fracture

In an anteromedial coronoid fracture, the mechanism of injury is in the opposite direction of that of a tip fracture. A varus and posteromedial

**Figure 2**

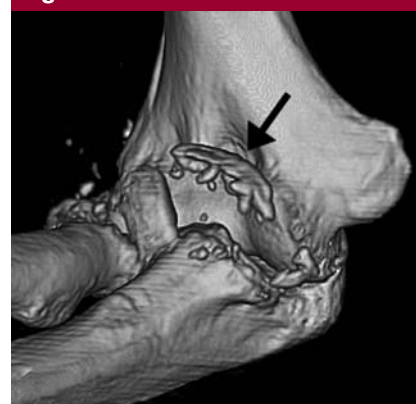

Axial view of fracture of the tip of the coronoid process seen in conjunction with posterolateral rotatory instability of the elbow (ie, terrible triad). AM = anteromedial. (Reproduced from O'Driscoll SW, Jupiter JB, Cohen MS, Ring D, McKee MD: Difficult elbow fractures: Pearls and pitfalls. *Instr Course Lect* 2003;52:113-134.)

rotation force on the forearm results in rupture of the LCL from its humeral origin. As the LCL gives way, the medial coronoid process is forced against and under the medial trochlea. Because of the shape of the medial coronoid process, this action will result in a fracture of the process that involves primarily the anteromedial portion. The size of the coronoid fracture will depend on the degree of force imparted to the elbow. An important determinant of stability is the level of involvement of the sublime tubercle, which is the insertion point of the MCL. When the sublime tubercle is involved in the fracture, medial elbow instability is likely.

When a significant anteromedial coronoid fracture is missed and left untreated, the ulnohumeral joint will tend to articulate incongruently under gravitational varus stress. Because the LCL is often torn, the lateral articulation of the trochlea will gap open, resulting in increased stress on the remaining cartilage on the medial aspect of the trochlea. A further result of such injury is relatively early onset of arthritic changes at the ulnohumeral joint. For this reason, anteromedial coronoid frac-

**Figure 3**



Three-dimensional computed tomography scan of an anteromedial coronoid fracture. The arrow indicates the fracture fragment.

tures should be identified early, before degenerative changes have occurred. Once significant arthritic changes are present, few therapeutic options are available other than total elbow arthroplasty.

### Biomechanical Studies

For a large anteromedial coronoid fracture with associated joint subluxation, the need for surgical fixation is clear because closed reduction techniques have not proved to be successful. Recent studies have sought to define the minimum size and the shape of a coronoid fracture that would require surgical intervention to regain stability.<sup>4,6-8</sup> Some authors have recommended surgical fixation for most coronoid fractures, but this view has not been borne out either clinically or in biomechanical studies.<sup>9</sup> Because many coronoid fractures are rarely isolated—that is, they usually occur in combination with injuries to other structures around the elbow—efforts are ongoing to determine the role and importance of the coronoid process in maintaining stability of the elbow joint. The ligament injuries associated with a small coronoid fracture may play a more important role in

**Table 2****Injury Patterns Suggestive of Varus Posteromedial and Valgus Posterolateral Rotatory Instability**

Varus Posteromedial Rotatory Instability
No radial head fracture
Coronoid fracture >15%
Posterior band of MCL ruptured
LCL complex avulsion
Most of the anterior band of the MCL intact
Valgus Posterolateral Rotatory Instability
Radial head fracture
Coronoid fracture <15%
LCL complex avulsion
Anterior band of MCL ruptured

LCL = lateral collateral ligament,  
MCL = medial collateral ligament

elbow instability than does the fracture itself.

Investigators in a recent biomechanical study simulated a Regan and Morrey type I fracture.<sup>9</sup> Testing was done in stable and MCL-deficient elbows. Varus and valgus motion was measured during gravity-loaded flexion. With intact ligaments, there was only a small increase in valgus angulation after a type I fracture. In the MCL-deficient elbows, there was no change in kinematics with or without a coronoid fracture. MCL repair was thought to be more important than type I coronoid fracture fixation.<sup>10</sup>

Closkey et al<sup>6</sup> studied the effects of a transverse fracture of the coronoid process with an applied axial load, similar to the Regan-Morrey type III fracture. The authors found no significant difference at any degree of flexion in the amount of posterior displacement between intact elbows and elbows in which  $\leq 50\%$  of the coronoid process was fractured. The study recommended non-surgical treatment for fractures involving  $<50\%$  of the process. It is important to note that this study did

not examine the contribution of the medial and lateral ligamentous structures to elbow stability, that coronoid fractures likely are not the result of a pure axial force, and that the coronoid process does not fracture in a pure transverse direction in the coronal plane.

Hull et al<sup>7</sup> examined the role of the coronoid process in varus osteoarticular elbow stability. After progressive transverse cuts of the coronoid process were made, resistance to varus stress was measured. Removal of 25%, 33%, and 40% of the process had no effect on constraining load at any flexion angle of the elbow. Following removal of 50% of the process, a statistically significant ( $P < 0.003$ ) decrease in the load resisting varus displacement was recorded. As in the study by Closkey et al,<sup>6</sup> the additional effect of the medial and lateral ligaments in providing stability was not examined. However, the study by Hull et al<sup>7</sup> suggests that the bony contribution of the coronoid process to elbow stability may not be significant when  $<25\%$  of the process is fractured.

Schneeberger et al<sup>8</sup> assessed the contribution of the radial head and coronoid process to posterolateral rotatory stability of the elbow. Removal of 30% of the coronoid process and the entire radial head resulted in complete ulnohumeral dislocation at 60° of elbow flexion. However, when the radial head was replaced with a metallic implant, stability was restored even though 30% of the coronoid process was absent. A defect of 50% of the coronoid process combined with a radial head defect could not be stabilized by radial head replacement alone. The data from this report reaffirm the importance of repairing or replacing the radial head in the presence of posterolateral rotatory instability (ie, terrible triad). Additionally, when a small coronoid fracture ( $<30\%$ ) is present, ulnohumeral stability may be achieved by focusing the surgical

plan on restoring the radial head and repairing the collateral ligaments.

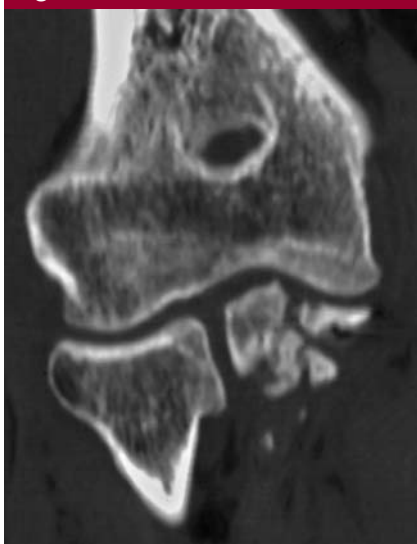Deutch et al<sup>11</sup> examined the stability of the elbow when it is subjected to rotational stress. When the coronoid process was fractured and the radial head excised, the joint subluxated regardless of the collateral ligament status. LCL reconstruction prevented major laxity even in the absence of a radial head. Replacement of the radial head and reconstruction of the LCL resulted in greater stability. The LCL was thought to be the prime stabilizer to external rotation.

### Surgical Exposures and Fixation Techniques

The two main indications for surgical repair of a coronoid process fracture are the presence of varus posteromedial rotatory instability and valgus posterolateral rotatory instability<sup>12,13</sup> (Table 2). However, the surgeon also must consider the size and morphology of the coronoid fracture, elbow stability, and injuries to associated structures. The complexity of these considerations and the lack of published data make it impossible to present an exact set of indications for coronoid fixation. When radiographs show obvious subluxation of the ulnohumeral joint and an associated large coronoid fracture, surgical stabilization is necessary. It is helpful to perform a fluoroscopic evaluation with the patient under anesthesia in the operating room to assess elbow stability. In this important first step, the surgeon may be able to discern which ligamentous structures are incompetent, which are intact, and whether the elbow is stable. Varus and valgus stress should be applied with supination and pronation at different flexion angles to fully assess the bony and ligamentous stability of the elbow. This motion is best performed with the arm abducted fully so as to minimize motion at the shoulder.



Figure 4

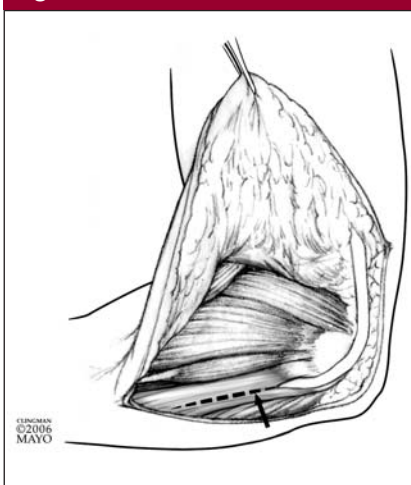


Anteroposterior computed tomography scan of the elbow demonstrating a severely comminuted coronoid fracture.

### Varus Posteromedial Rotatory Instability

Varus posteromedial rotatory instability often presents as an incongruent ulnohumeral joint on preoperative radiographs or CT. Collapse and loss of the medial ulnohumeral joint space will be visible, along with the coronoid process fracture. Often, the radial head is not fractured. The coronoid fracture will typically involve  $\geq 20\%$  of the anteromedial process. The surgical approach to this condition involves repair of the LCL to regain ligamentous stability combined with internal fixation of the coronoid fracture. It is highly advisable to obtain a preoperative CT scan to confirm the coronoid fracture pattern. Severe comminution may be difficult to repair with plates or screws; if such injury is seen, the surgical approach may be limited to the lateral side to repair the LCL, in conjunction with placement of an external fixator to unload the medial side and prevent varus stress while the coronoid fracture heals. Exposing a comminuted coronoid fracture with a medial surgical approach may impart additional trauma without

Figure 5



In situ release of the ulnar nerve and exposure of the proximal ulna via a split incision of the flexor carpi ulnaris muscle (arrow). (Reproduced with permission from the Mayo Foundation.)

providing additional stability (Figure 4).

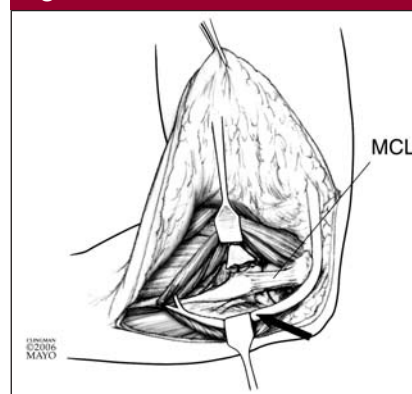
### Valgus Posterolateral Rotatory Instability

Valgus posterolateral rotatory instability usually presents as an elbow dislocation with radial head fracture and a small coronoid fracture.<sup>14</sup> In this situation, a lateral approach to the elbow may be used to repair or replace the radial head. If the radial head is excised and replaced, the coronoid fracture, if small, can be ignored or, if it is loose in the joint, excised. A large coronoid fracture should be treated with screw fixation from a posterior ulna approach.

### Approach for Anteromedial Coronoid Process Fracture

For an anteromedial coronoid fracture, the author generally prefers a posterior skin incision to approach the elbow because this allows development of medial and lateral flaps through a single incision. A posterior incision also will allow an approach through a watershed area to avoid injury to branches of the brachial and antebrachial sensory nerves. As an al-

Figure 6



Exposure of the coronoid process. The flexor pronator group is elevated and retracted anteriorly and laterally. The ulnar nerve is retracted posteriorly (arrow). The flexor pronator group is not detached from the humerus. MCL = medial collateral ligament. (Reproduced with permission from the Mayo Foundation.)

ternative, two incisions can be made, one medial and centered over the medial epicondyle and the other lateral and over the lateral epicondyle. It is easiest to perform the posterior incision with the patient in the supine position with the arm placed across the chest. When a posterior incision is used, the medial flap is developed first, thereby exposing the ulnar nerve and the origins of the flexor pronator group.

The ulnar nerve does not need to be routinely transposed in the approach to the coronoid process, but it should be released in situ and retracted posteriorly during the procedure (Figure 5). If the ulnar nerve is thought to have been traumatized as a result of the injury, the surgeon may prefer to transpose the nerve anteriorly at the end of the procedure.

As the ulnar nerve is retracted posteriorly, the muscles of the flexor/pronator group anterior to the ulnar nerve are carefully elevated off the ulna in a distal-to-proximal direction to expose the sublime tubercle, the coronoid process, and the MCL (Figure 6). It is easiest to approach the

**Figure 7**

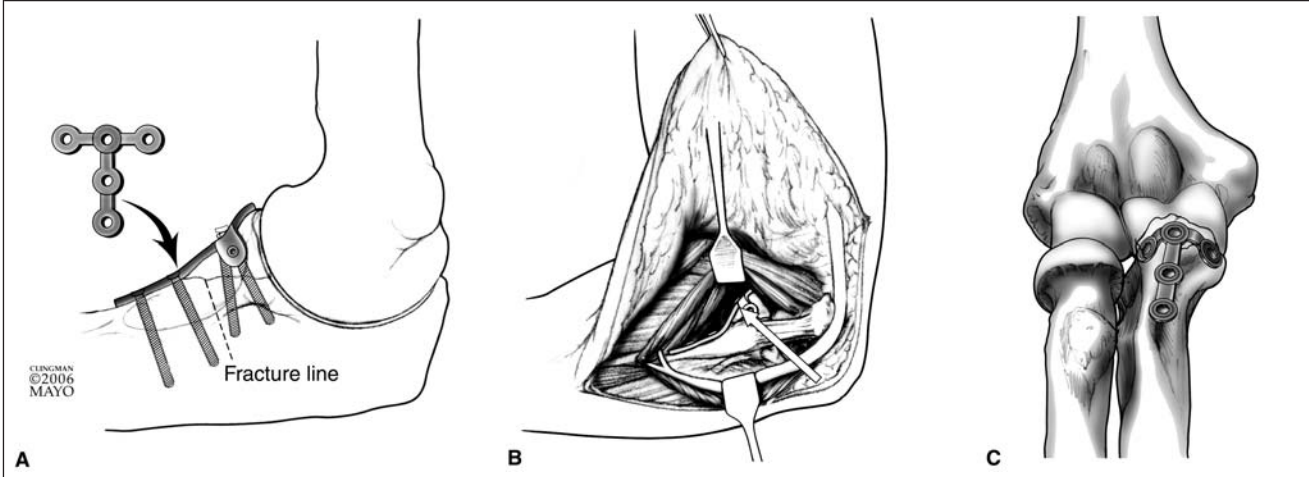
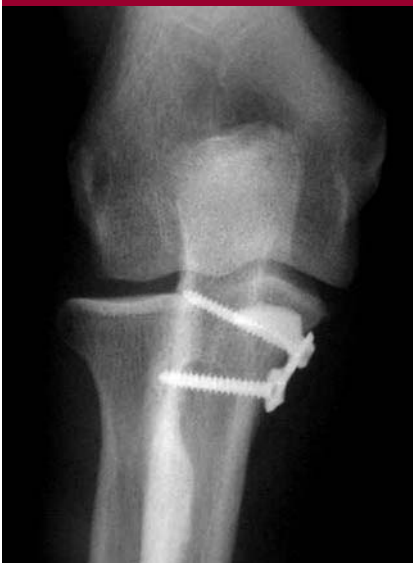

Plate positioning of the coronoid process. **A**, Medial view of the plate on the ulna. **B**, Medial approach through the flexor carpi ulnaris. The arrow indicates the location of the plate. **C**, Anterior view of the plate on the ulna. (Reproduced with permission from the Mayo Foundation.)

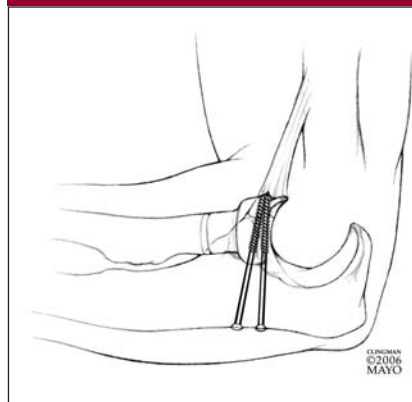
**Figure 8**



Anteroposterior radiograph of plate fixation of an anteromedial coronoid fracture.

sublime tubercle and MCL from distal to proximal because there is a clear transition from the muscle portion distally to the fibrous insertion of the MCL onto the sublime tubercle. It can be more difficult to begin the exposure from proximal to distal because the fibrous origin of the flexor/

**Figure 9**



Posterior screw fixation of a coronoid fracture. (Reproduced with permission from the Mayo Foundation.)

pronator group and the MCL tend to blend together.

Once the coronoid is exposed, the fracture is stabilized initially with a large clamp or by Kirschner wire (K-wire) fixation. Definitive fixation can then be achieved with a small plate or with screws. Precontoured coronoid plates are now available from several suppliers to facilitate this step. The primary role of the plate is to provide a buttress against posterior subluxation of the ulna in

relation to the humerus (ie, push plate) (Figures 7 and 8). Screw fixation can be performed most easily with the use of an anterior cruciate ligament (ACL) drill guide to allow placement of partially threaded cannulated screws from the posterior aspect of the ulna. The ACL guide allows the surgeon to accurately place a guidewire into the correct area of the coronoid process and avoid intra-articular penetration. Usually, two screws are needed for adequate fracture stabilization (Figure 9). The presence of the overlying flexor pronator muscle group can make it difficult to place screws accurately from an anterior approach. Small threaded K-wires can sometimes be placed from an anterior approach and then cut flush with the surface of the coronoid process.

Following stabilization of the coronoid fracture, the LCL, which is almost always torn in this injury pattern, is repaired. Once the lateral skin flap is raised, tearing of a portion of the lateral common extensor tendon may be noted, which allows access to the LCL complex. If there is no obvious tearing of the common extensor tendon, then a Kocher approach to the

elbow is performed. The avulsed LCL can then be identified and the repair performed. It is recommended that the repair of the LCL and common extensor origin back to the lateral epicondyle be made in one layer for greater strength. This can be done with a no. 2 braided suture in a locking fashion, placed either through drill holes in the lateral epicondyle or with suture anchors. It is crucial to obtain a stable, strong repair of the LCL because this is the prime ligamentous constraint against varus instability of the elbow.

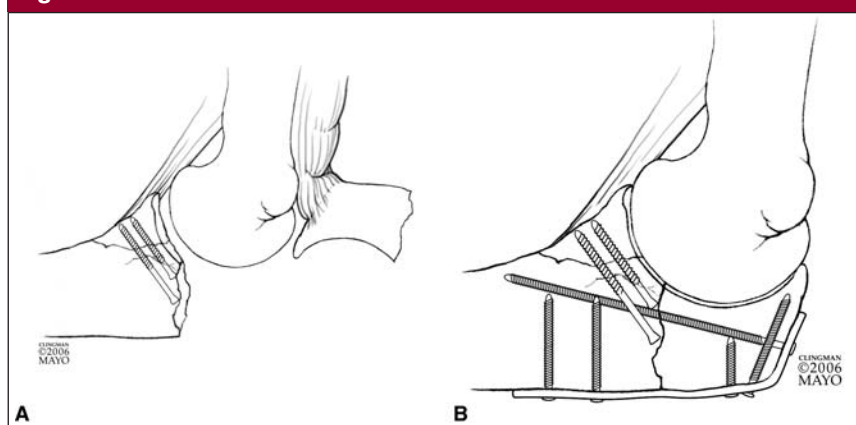
On occasion, a significant coronoid fracture will be associated with a transolecranon fracture. In such situations, the coronoid fracture can be exposed and fixed by working through the fracture of the olecranon. If the proximal portion of the olecranon is retracted, the coronoid fracture may often be visualized and then stabilized with internal fixation (Figure 10).

### Approach for Coronoid Tip Fracture

The surgical approach to the common elbow instability pattern of a coronoid process tip fracture may be made either through a posterior skin incision or a direct lateral approach. A posterior incision is preferred because of its versatility in allowing medial and lateral exposure of the elbow through a single incision. After a posterior incision is made, a lateral flap is developed, exposing the lateral epicondyle and the common extensor tendon. Often with a terrible triad injury, a rent is seen in the common extensor tendon. This can be used as an avenue for exposure of the LCL and radial head. When no obvious defect in the tendon is encountered, a direct approach on the fractured radial head is preferred. This approach is made through an incision in the common extensor tendon, which is directly overlying the radial head. A Kocher approach can be used, but this will put the surgical plane more posterior to the radial head.

After exposure of the fractured ra-

**Figure 10**



Fixation of a coronoid fracture combined with a transolecranon fracture. **A**, The coronoid fracture is fixed with headless buried screws, with the olecranon fracture and triceps retracted. **B**, The olecranon fracture is then reduced, and internal fixation is performed with an olecranon plate and longitudinal screw. (Reproduced with permission from the Mayo Foundation.)

dial head is achieved, a decision is made to perform either fracture fixation or replacement. Visualization of the coronoid fracture is easiest when the radial head is comminuted and requires removal. When only a portion of the radial head is fractured, visualization of the coronoid process is quite difficult. In this situation, it is necessary to review the CT scan and determine the size of the coronoid fracture. If the CT scan shows that  $\leq 15\%$  of the coronoid process is fractured, the process does not need to be internally fixed; however, the radial head fracture needs to be stabilized securely or radial head replacement performed.

In the presence of coronoid fracture magnitude  $>15\%$ , the fracture can be repaired by either a suture technique or a screw technique. The suture technique involves use of an ACL guide to make accurate K-wire tunnels into the coronoid fracture site from the posterior ulna (Figure 11). Next, strong braided no. 2 suture is used to lasso the coronoid fracture and anterior capsule; the sutures are passed through the K-wire holes to the posterior border of the ulna. The sutures are then tied down to reduce the coronoid fracture (Figure 12). The

sutures are best tied at the end of the procedure because manipulation of the elbow during radial head replacement may disrupt the repair. The strength of this suture repair technique has never been biomechanically tested and likely does not provide a significant buttress to displacement forces. A cadaveric study examined the contribution of suture fixation of type I coronoid fracture (tip fracture) and found no effect on elbow kinematics.<sup>9</sup> The author does not use this technique as frequently as in the past because biomechanical studies have shown minimal instability associated with small coronoid fractures.<sup>4,6,8,10</sup>

The screw technique for coronoid fracture reduction involves use of a large clamp and an ACL drill guide. The surgeon reduces the fracture using a large clamp while visualizing from the lateral side through the radial head defect. The ACL drill guide is placed from the dorsal ulnar surface to the tip of the coronoid process. A guidewire for the screw is then placed through the ACL guide to exit at the tip of the process, off the articular surface. The visible surface area over the tip of the process is small. For this reason, an ACL drill guide can help



improve accuracy in the placement of the guidewire. A partially threaded cannulated screw can then be placed in the coronoid process to provide some compression to the fracture. Typically, two screws are needed to

reduce a coronoid fracture in this manner (Figure 9).

After the coronoid fracture is accurately reduced, the radial head is replaced with a metallic implant or repaired with internal fixation using

screws or a plate. The radial head replacement should be of equal height with the coronoid tip and should be flush with the articular surface of the coronoid process. The surgeon should strive not to overstuff the joint but rather err on the side of slightly undersizing the radial head. The LCL and common extensor complex are then repaired back to the lateral epicondyle with the use of suture passed through drill holes in the epicondyle or with suture anchors. An accurate, intact repair of the LCL will help protect the coronoid fixation by limiting the amount of varus force at the fracture site (Figure 13).

**Figure 11**

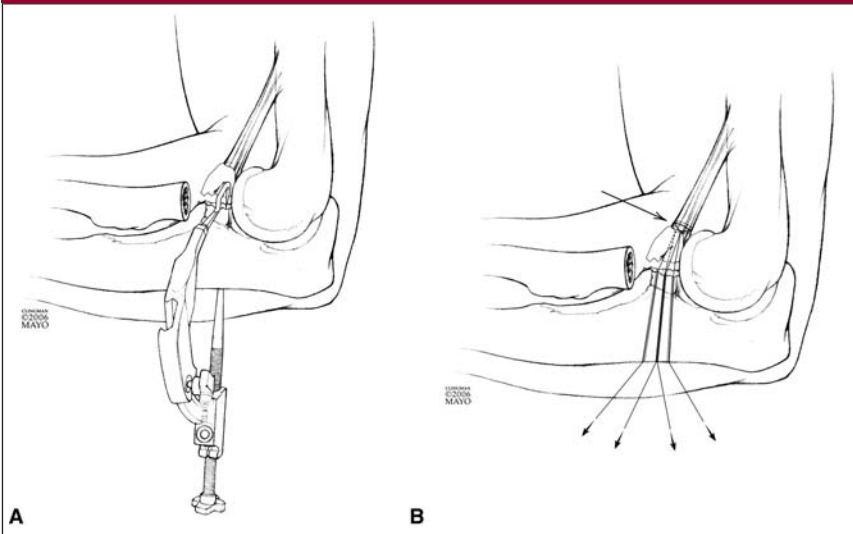
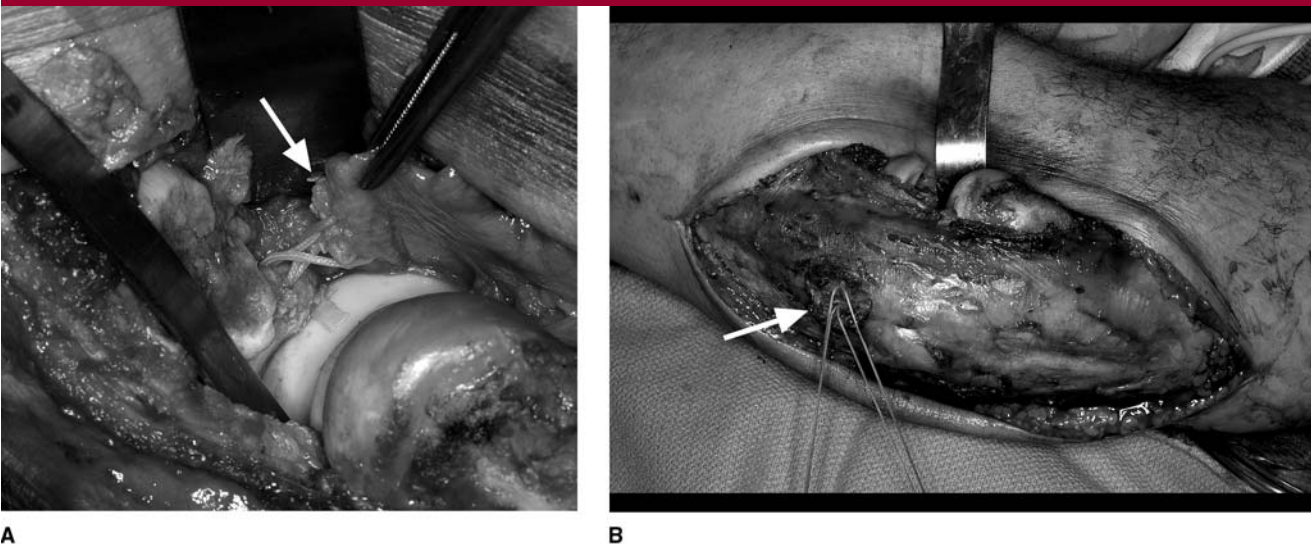


Illustration of suture technique for fixation of a small coronoid fracture. **A**, For suture reduction, an anterior cruciate ligament guide is helpful for placing accurate drill holes into the coronoid fracture. **B**, Suture is placed over the small coronoid fracture, incorporating the anterior capsule (arrow). The suture tails are pulled down through the ulna (small arrows) and then tied. (Reproduced with permission from the Mayo Foundation, 2006.)

**Postoperative Care**

Postoperative motion following repair of a coronoid fracture associated with posteromedial rotatory instability is dependent on the security of the fixation. Varus forces occur in the elbow with activities of daily living, so the trochlea will have a tendency to push the coronoid fracture away from a reduced position. For this reason, plate fixation is done mainly for the buttress effect. Varus

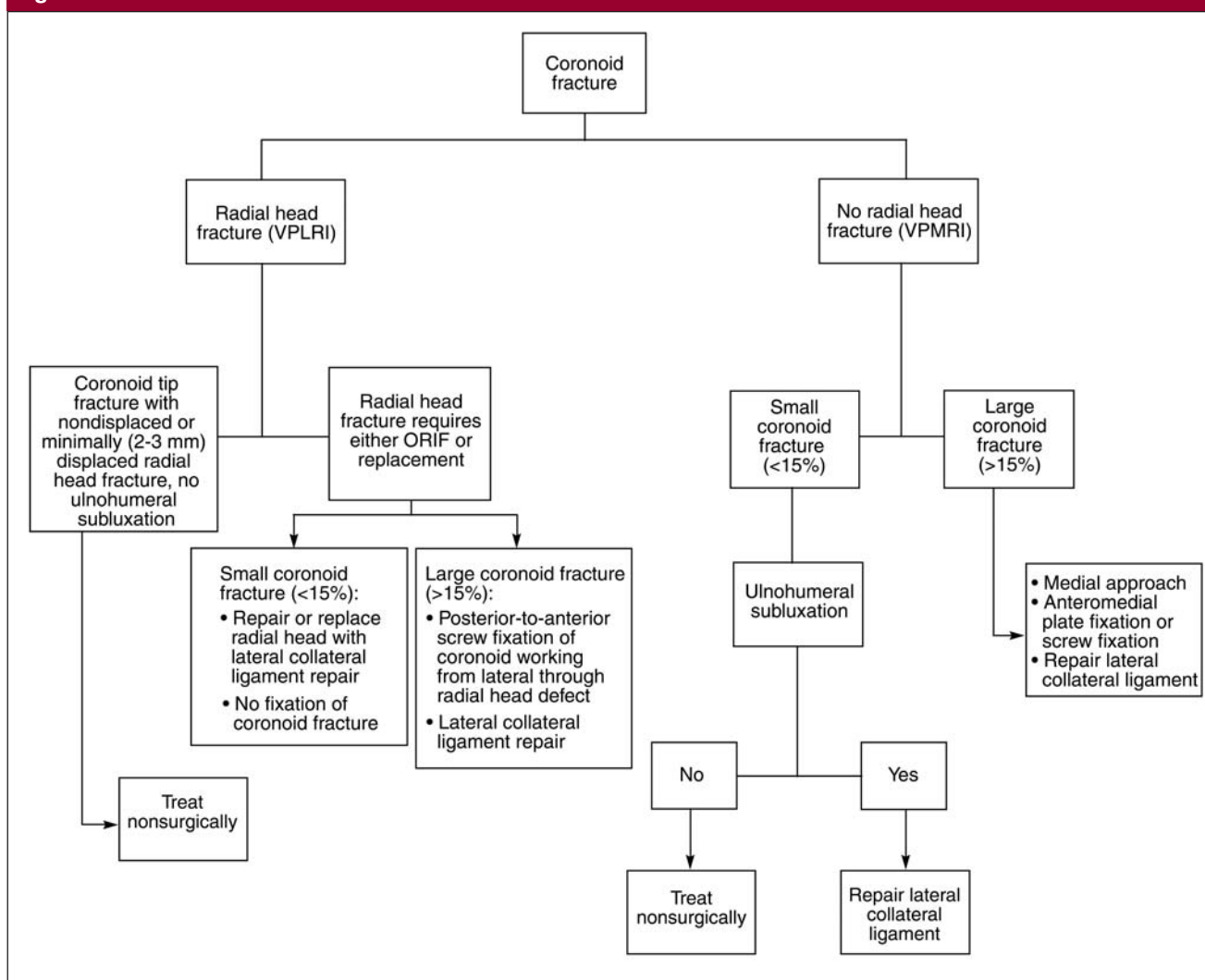
**Figure 12**



Suture technique for fixation of a small coronoid fracture. **A**, The forceps hold the coronoid fragment (arrow). The radial head has been resected before replacement. **B**, Sutures (arrow) are pulled through drill holes in the posterior ulna.



Figure 13



Algorithm for the treatment of coronoid fractures. ORIF = open reduction and internal fixation, VPLRI = valgus posterolateral rotatory instability, VPMRI = varus posteromedial rotatory instability

forces also tend to pull apart the lateral ligamentous repair. Provided that the lateral repair and the bony fixation are deemed secure, gentle motion may be started within a few days after surgery.

When the surgical repair is tenuous, two options exist. The elbow (ie, arm and forearm) may be placed into a cast or brace. Or, if potential instability is recognized during surgery, an external fixator can be placed on the lateral aspect of the elbow. This commonly is a hinged type of fixator, but a static fixator may also be used. The purpose of the

fixator is to neutralize the varus forces and unload the force on the coronoid fracture fragment and the reconstructed lateral ligament complex.

After a posterolateral rotatory injury (terrible triad) is stabilized, controlled motion can usually be started a few days after surgery. Because the coronoid fracture associated with this injury pattern is usually small and does not involve the anteromedial facet, varus gravitational forces affect only the lateral ligament complex, so an external fixator is rarely needed. The main concern

with this injury pattern is the stability of the radial head. If the radial head is stable after fixation or replacement, then motion can be initiated within the first week after surgery.

### Potential Complications

Several possible complications from surgery merit concern. Heterotopic ossification is one possible complication, and postoperative prophylaxis to prevent it may be considered for some patients. Either nonsteroidal anti-inflammatory drugs or radiation

may be used. Nonunion of a coronoid fracture is unusual, but either of those treatments may in theory negatively affect fracture healing. Predicting which patients will develop heterotopic ossification is not possible; it has occurred after arthroscopy of the elbow, and yet in many severe trauma cases it does not occur.

Stiffness after surgical repair of a coronoid fracture can be addressed after fracture healing has occurred. Significant heterotopic bone can be surgically resected once the bone is radiographically mature, often by 3 to 4 months after surgery. This is followed postoperatively by use of continuous passive motion or static adjustable splints. Continuous passive motion has not yet been shown to be more beneficial than the use of splints. Patients who develop capsular contractures after coronoid fracture surgery can also be treated with static splinting. Many of these patients will achieve functional motion with a combination of splints and exercise; surgical release is needed for or requested by only a small number of patients.

## Results and Complications

The literature contains few reports on the outcomes of treatment or nontreatment for coronoid process fractures. Only recently has the significance of a coronoid fracture been examined in the context of complex elbow instability. In prior reports, emphasis was placed on the obvious fractures of the radial head, distal humerus, and ulna. Few observations were made regarding the contribution of coronoid fracture to overall fracture stability.

A recent report specifically examined 11 patients with combined radial head and coronoid fractures.<sup>15</sup> The radial head was either replaced or repaired in nine patients, and the coronoid fracture was not repaired in any patient. Five patients suffered redis-

location after surgery. The treatment was rated as unsatisfactory for 7 of the 11 patients. Because the coronoid fractures were not treated, this report illustrates the adverse outcome that can occur when the coronoid fracture component of an injury is not addressed.<sup>15</sup>

In a follow up-report, Doornberg and Ring<sup>16</sup> examined 18 patients who were treated for a coronoid fracture. Anteromedial plate fixation was used in nine patients, screw fixation in one, and suture fixation in one. Seven patients were treated nonsurgically. Most patients had an avulsion of the LCL complex. At follow-up, six patients had malalignment of the anteromedial coronoid process with resultant varus subluxation of the elbow and ulnohumeral arthrosis. Secure fixation of the coronoid process resulted in good elbow function. This report, similar to the previous study, underscores the importance of identifying and treating the coronoid fracture component of complex elbow trauma. Potential complications of coronoid fractures are similar to those of other complex elbow injuries. Elbow contracture, heterotopic ossification, and ulnar neuropathy can occur. Subluxation of the ulnohumeral joint with an untreated or poorly reduced coronoid fracture can result in arthrosis.

## Summary

Fractures of the coronoid process occur as a consequence of complex instability of the elbow. Unlike radial head fractures, coronoid fractures may be subtle on conventional radiographs. When a coronoid fracture is associated with a varus instability pattern, the LCL complex will have to be repaired or reconstructed and the coronoid fracture fixed. Techniques for repair of the fractured coronoid process include suture repair, use of contoured buttress plates, and screw fixation. Postoperative treatment includes avoidance of varus forces and progressive mobi-

lization of flexion and extension. If the coronoid fracture is associated with a valgus instability pattern, the often small fracture can be ignored and the associated radial head fracture can be repaired or replaced. Recent biomechanical studies have demonstrated the important role of the coronoid process in elbow stability. Proper treatment algorithms will be developed in the future as clinical studies demonstrate objective outcome data.

## References

*Evidence-based Medicine:* There are no level I or II randomized prospective studies referenced. Sources are largely level III case-control and cohort studies or level IV case reports based on author/surgeon experience. References 5 and 12 are expert opinion.

Citation numbers printed in **bold type** indicate references published within the past 5 years.

1. Doornberg JN, Ring D: Coronoid fracture patterns. *J Hand Surg Am* 2006; 31:45-52.
2. Josefsson PO, Gentz CF, Johnell O, Wendeborg B: Dislocations of the elbow and intraarticular fractures. *Clin Orthop Relat Res* 1989;246:126-130.
3. Doornberg JN, de Jong IM, Lindenhovius AL, Ring D: The anteromedial facet of the coronoid process of the ulna. *J Shoulder Elbow Surg* 2007;16: 667-670.
4. Regan W, Morrey B: Fractures of the coronoid process of the ulna. *J Bone Joint Surg Am* 1989;71:1348-1354.
5. O'Driscoll SW, Jupiter JB, Cohen MS, Ring D, McKee MD: Difficult elbow fractures: Pearls and pitfalls. *Instr Course Lect* 2003;52:113-134.
6. Closkey RF, Goode JR, Kirschenbaum D, Cody RP: The role of the coronoid process in elbow stability: A biomechanical analysis of axial loading. *J Bone Joint Surg Am* 2000;82:1749-1753.
7. Hull JR, Owen JR, Fern SE, Wayne JS, Boardman ND III: Role of the coronoid process in varus osteoarticular stability of the elbow. *J Shoulder Elbow Surg* 2005;14:441-446.
8. Schneeberger AG, Sadowski MM, Ja-

- cob HA: Coronoid process and radial head as posterolateral rotatory stabilizers of the elbow. *J Bone Joint Surg Am* 2004;86:975-982.
9. Beingsner DM, Stacpoole RA, Dunning CE, Johnson JA, King GJ: The effect of suture fixation of type I coronoid fractures on the kinematics and stability of the elbow with and without medial collateral ligament repair. *J Shoulder Elbow Surg* 2007;16:213-217.
  10. Morrey BF, Tanaka S, An KN: Valgus stability of the elbow: A definition of primary and secondary constraints. *Clin Orthop Relat Res* 1991;265:187-195.
  11. Deutch SR, Jensen SL, Olsen BS, Sneppen O: Elbow joint stability in relation to forced external rotation: An experimental study of the osseous constraint. *J Shoulder Elbow Surg* 2003;12:287-292.
  12. McKee MD, Pugh DM, Wild LM, Schemitsch EH, King GJ: Standard surgical protocol to treat elbow dislocations with radial head and coronoid fractures: Surgical technique. *J Bone Joint Surg Am* 2005;87(suppl 1 pt 1):22-32.
  13. Ring D, Hannouche D, Jupiter JB: Surgical treatment of persistent dislocation or subluxation of the ulnohumeral joint after fracture-dislocation of the elbow. *J Hand Surg Am* 2004;29:470-480.
  14. Pugh DM, Wild LM, Schemitsch EH, King GJ, McKee MD: Standard surgical protocol to treat elbow dislocations with radial head and coronoid fractures. *J Bone Joint Surg Am* 2004;86:1122-1130.
  15. Ring D, Jupiter JB, Zilberfarb J: Posterior dislocation of the elbow with fractures of the radial head and coronoid. *J Bone Joint Surg Am* 2002;84:547-551.
  16. Doornberg JN, Ring DC: Fracture of the anteromedial facet of the coronoid process. *J Bone Joint Surg Am* 2006;88:2216-2224.